

A Summary of Expert Consensus Recommendations for Multimodality Imaging in Cardiac Amyloidosis

Adapted from ASNC/AHA/ASE/EANM/HFSA/ISA/
SCMR/SNMMI* Expert Consensus Recommendations for
Multimodality Imaging in Cardiac Amyloidosis: Evidence
Base and Standardized Methods of Imaging and Diagnostic
Criteria and Appropriate Utilization, Parts 1 and 2



Multisocietal Expert Consensus RECOMMENDATIONS

Standardising the Diagnostic Multimodality Cardiac Amyloidosis Imaging Approach¹

The standardisation for using echocardiography, cardiac magnetic resonance (CMR), and radionuclide imaging in the evaluation of cardiac amyloidosis is an unmet need that could potentially increase diagnosis and improve quality of care and patient outcomes for this highly morbid, underdiagnosed disease.

Cardiac amyloidosis is a group of diseases that is life threatening and remains largely underrecognised or delayed in diagnosis due to many factors, and there is a lack of clear diagnostic imaging guidelines

Despite an abundance of noninvasive cardiac imaging options for the evaluation of cardiac amyloidosis, there is a lack of consensus on their clinical utility, which is problematic considering the importance of early diagnosis

In response, a group of experts in cardiovascular imaging and amyloidosis established an international consensus report to guide the appropriate clinical utilisation of imaging in cardiac amyloidosis

THIS FIRST INTERNATIONAL MULTISOCIETAL CONSENSUS REPORT PRESENTS^{1*}

Evidence

on the effectiveness of echocardiography, CMR, and radionuclide imaging in the screening, diagnosis, and management of cardiac amyloidosis

Defined, standardised protocols

for the gathering, analysis, and reporting of these noninvasive imaging techniques in the assessment of cardiac amyloidosis

Consensus on diagnostic criteria

for cardiac amyloidosis, identifying clinical indications and providing recommendations on appropriate utilisation in these clinical scenarios

No existing noninvasive tools can individually diagnose cardiac amyloidosis or confirm aetiologic subtype, **which necessitates a multimodal cardiac imaging approach** that includes¹:

Raising suspicion

- **Echocardiography** to assess **structure and function**, frequently used in patients with concerning cardiac symptoms
- **CMR** to provide **tissue characterization** as well as high-resolution morphologic and functional assessment, while also offering differentiation of cardiac amyloidosis from other cardiomyopathies and potentially early detection of cardiac amyloidosis

Reaching a definitive diagnosis

- **Radionuclide (^{99m}Tc-PYP/^{99m}Tc-DPD) imaging** to assist in the **noninvasive diagnosis** of transthyretin amyloid cardiomyopathy (ATTR-CM) with high sensitivity and specificity when combined with testing to rule out AL amyloidosis

Cardiac amyloidosis is a cardiomyopathy resulting from the myocardial accumulation of misfolded protein deposits, or amyloid fibrils.

Cardiac amyloidosis most commonly results from 1 of the following 2 protein precursors:

- Immunoglobulin light chain amyloid fibril protein (AL)—amyloid fibrils form from misfolded monoclonal immunoglobulin light chain protein produced by bone marrow plasma cells
- Transthyretin amyloid fibril protein (ATTR)—amyloid fibrils form from misfolded transthyretin (TTR), a serum transport protein for thyroid hormone and retinol that is synthesised primarily by the liver

Exclusion of a monoclonal process with serum/urine immunofixation and a serum free light chain (FLC) assay in all patients with suspected amyloidosis is critical.¹

^{99m}Tc-DPD, ^{99m}technetium-labelled 3,3-diphosphono-1,2-propanodicarboxylic acid; ^{99m}Tc-PYP, ^{99m}technetium-labelled pyrophosphate.

*Cardiac amyloidosis, including both AL and ATTR types.¹

Echocardiography

Echocardiography as a Cardiac Imaging Modality

BASIS OF EVIDENCE

Echocardiography plays a major role in the noninvasive diagnosis of cardiac amyloidosis due to its wide availability and capacity to assess **structure and function**.¹

Cardiac amyloidosis is suggested on echocardiography when¹:

- Morphological findings related to amyloid infiltration show increased left ventricular (LV) wall thickness (>1.2 cm) and increased LV mass in the absence of any other plausible causes of LV hypertrophy
- Increased echogenicity of the myocardium (sparkling) is identified in conjunction with severely reduced longitudinal LV function
- Any of the following echocardiographic findings are present:
 - Normal to small LV cavity size
 - Right ventricular and interatrial septal thickening
 - Biatrial enlargement and dysfunction
 - Pericardial effusion
 - Left atrial (LA) and LA appendage stasis and thrombi
 - Tissue Doppler imaging (TDI) <5 cm/s
 - Thickened valves
- Results indicate impaired LA reservoir and pump functions, possibly resulting in the formation of atrial and atrial appendage thrombi
- Presence of discordance of QRS voltage to echocardiographic LV wall thickness
- On speckle-tracking echocardiography (STE), a pattern of reduced longitudinal shortening with preserved LV ejection fraction and radial shortening can be seen
 - STE can differentiate cardiac amyloidosis from other causes of increased LV wall thickness
 - STE can also refine the noninvasive recognition of disease by quantitating longitudinal systolic function
 - A pattern of distribution of STE-derived longitudinal strain in which basal LV segments are severely impaired while apical segments are relatively spared is commonly observed in patients with cardiac amyloidosis

Echocardiography PROS AND CONS¹

Pros

- Portability, bedside availability, widespread availability
- Superior diastolic function assessment
- A critical component of the diagnostic evaluation and management of patients with cardiac amyloidosis

Cons

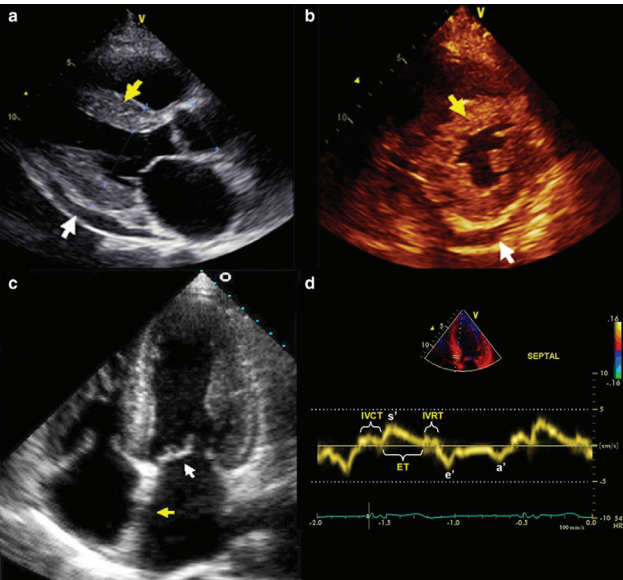
- Not sufficient to diagnose cardiac amyloidosis on its own
- Lacks tissue characterisation provided by cardiovascular magnetic resonance (CMR)
- Cannot distinguish immunoglobulin light chain amyloidosis (AL) from transthyretin amyloid cardiomyopathy (ATTR-CM), requiring evaluation to exclude AL and further imaging studies to definitively diagnose ATTR-CM

KEY RECOMMENDATIONS FOR THE ROLE OF ECHOCARDIOGRAPHY WHEN CARDIAC AMYLOIDOSIS IS SUSPECTED¹

- Perform comprehensive 2D echocardiography, including quantitative TDI and STE, in all patients with unexplained LV wall thickening and a clinical suspicion of cardiac amyloidosis
- Any echocardiographic abnormalities suggestive of cardiac amyloidosis should prompt further evaluation
- Combine echocardiographic parameters with electrocardiographic, clinical, biomarker, and other imaging findings to maximise diagnostic accuracy

CARDIAC AMYLOIDOSIS ON ECHOCARDIOGRAPHY¹

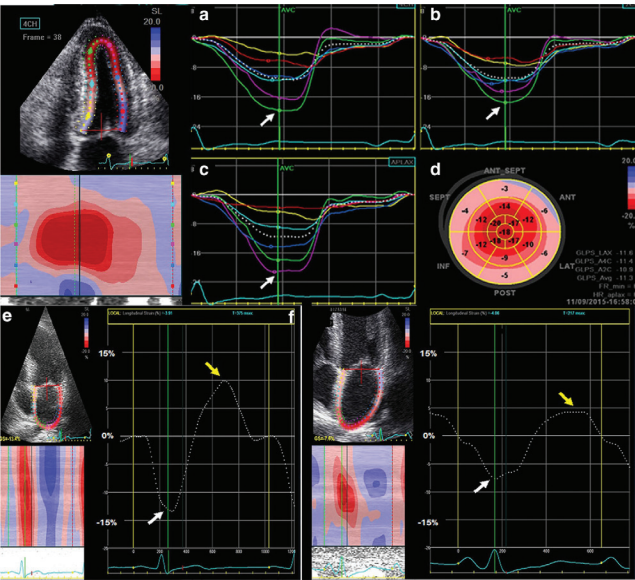
Characteristic Appearance



(a)-(d) 2D echocardiography. (a) (parasternal long axis) and (b) (parasternal short axis) demonstrate increased LV wall thickness with a sparkling texture of the myocardium (yellow arrows) in a patient with primary (AL) cardiac amyloidosis. Also, note the small pericardial effusion (white arrows), which is often seen in patients with cardiac amyloidosis. (c) (apical 4-chamber view) demonstrates increased biventricular wall thickness, biatrial enlargement, and increased thickening of the interatrial septum (yellow arrow) and mitral valve leaflets (white arrow) in a patient with wild-type transthyretin cardiac amyloidosis. (d) Tissue Doppler imaging (TDI) tracing taken at the septal mitral annulus in a patient with ATTR cardiac amyloidosis. The TDI tracings show the “5-5-5” sign (s’ [systolic], e’ [early diastolic], and a’ [late (atrial) diastolic] tissue velocities are all <5 cm/s), which is seen in patients with more advanced cardiac amyloidosis. The dotted lines denote the 5 cm/s cut-off for systolic and diastolic tissue velocities. In addition to the decreased tissue velocities, isovolumic contraction and relaxation times (IVCT and IVRT, respectively) are increased and ejection time (ET) is decreased, findings also seen in patients with cardiac amyloidosis especially as the disease becomes more advanced.

2D, 2-dimensional; ATTRv, variant ATTR.

Left Ventricular Longitudinal Strain Abnormalities



(a) (apical 4-chamber view), (b) (apical 2-chamber view), (c) (apical 3-chamber view) all show abnormal longitudinal strain in the basal and mid segments with relative preservation in the apical segments (purple and green curves, white arrows) in a patient with ATTRv cardiac amyloidosis. (d) shows the corresponding bull's-eye map of the longitudinal strain pattern throughout the left ventricle with the “cherry-on-the-top” sign (red denotes normal longitudinal strain at the apex and pink/blue denotes abnormal longitudinal strain at the mid/basal left ventricle).

Echocardiography as a Cardiac Imaging Modality, continued

STANDARDISED ACQUISITION, INTERPRETATION, AND REPORTING OF ECHOCARDIOGRAPHY FOR CARDIAC AMYLOIDOSIS¹

Parameter for acquisition and reporting	Abnormal parameter	Notes	Recommendations for reporting
2D, Colour, and Spectral Doppler Imaging			Required
LV wall thickness	Increased LV wall thickness (>1.2 cm) and increased relative wall thickness (>0.42)	Increased LV wall thickness relative to ECG QRS voltage is particularly suggestive	Required
Myocardial echogenicity	Increased echogenicity of the myocardium (sparkling, hyper-refractile “texture” of the myocardium)	Not highly specific (differential diagnosis includes ESRD or other infiltrative cardiomyopathies). However, this finding in conjunction with severely reduced longitudinal function of the LV is highly suggestive	Required
Atrial size and function	Atrial enlargement and dysfunction	Non-specific but important finding to support the diagnosis and potentially provide insight into risk for stroke or arterial embolism	Required
Interatrial septum and valves	Thickening of the interatrial septum and valves (>.5 cm)	Non-specific but suggestive of the diagnosis	Required
Pericardial effusion	Pericardial effusion	Non-specific, but when coupled with other echo signs is suggestive of the diagnosis	Required
Diastolic function	Grade 2 or worse diastolic dysfunction with high E/A ratio (>1.5) and reduced E deceleration time (<150 ms)	Doppler diastolic function is helpful in determining prognosis. Severely reduced A wave velocity can be due to LA failure, which can be helpful in determining risk of stroke	Required
Estimated PA systolic and right atrial pressure	Increased pressures (>35 mm Hg for PA, ≥10 mm Hg for RA)	These are important parameters to estimate volume status and optimise diuretic dosing	Required
Tissue Doppler Imaging			Required
Tissue Doppler velocities	Reduced tissue Doppler s', e', and a' velocities (all <5 cm/s)	If present, the “5-5-5” sign (all TDI velocities <5 cm/s) can be useful and is typically highly suggestive of the diagnosis but may not be sensitive for the diagnosis in early forms of the disease	Required

Parameter for acquisition and reporting	Abnormal parameter	Notes	Recommendations for reporting
Strain Imaging			Recommended
Longitudinal LV strain	Decreased global longitudinal LV strain (absolute value less than -15%)	2D and STE shows characteristic appearance of myocardial deformation in patients with cardiac amyloidosis	Recommended
Longitudinal LV strain bull's-eye map	“Cherry-on-the-top” sign on STE longitudinal strain bull's-eye map (preservation of apical longitudinal strain with severely abnormal basal and mid-LV longitudinal strain)	Characteristic bull's-eye pattern is likely the most specific sign to rule in the diagnosis of cardiac amyloidosis (but still does not differentiate ATTR vs AL amyloidosis)	Recommended
REPORTING OF ECHOCARDIOGRAPHY FINDINGS IN CARDIAC AMYLOIDOSIS			
An overall interpretation of the echo findings into categories of:			Required
● Not suggestive: Normal LV wall thickness, normal LV mass, normal atrial size, septal or lateral tissue Doppler e' velocity >10 cm/s			
● Strongly suggestive: Increased LV wall thickness, increased LV mass, typical LV longitudinal strain pattern, mitral annular TDI <5 cm/sec, biatrial enlargement, small A wave in sinus rhythm, small pericardial and/or pleural effusions			
● Equivocal: Findings not described above			
Interpret the echo results in the context of prior evaluation			Recommended
Provide follow-up recommendations:			Recommended
Strongly suggestive echocardiographic findings cannot distinguish AL from TTR cardiac amyloidosis			
Endomyocardial biopsy (EMB) is not always indicated in patients with strongly suggestive echo findings. Please see “Expert Consensus Recommendations for Diagnosis of Cardiac Amyloidosis” on back page for indications for endomyocardial biopsy			
Consider evaluation (1) to exclude AL amyloidosis, evaluate for plasma cell dyscrasia (serum and urine immunofixation, serum free light chain (FLC) assay and (2) to exclude ATTR cardiac amyloidosis, consider imaging with ^{99m} Tc-PYP/DPD			

2D, 2-dimensional; ^{99m}Tc-DPD, ^{99m}technetium-labelled 3,3-diphosphono-1,2-propanodicarboxylic acid; ^{99m}Tc-PYP, ^{99m}technetium-labelled pyrophosphate; A, late (atrial) mitral inflow velocity; AL, immunoglobulin light chain amyloid fibril protein; ATTR, transthyretin amyloid fibril protein; E, early mitral inflow velocity; E/A, ratio of early to late (atrial) mitral inflow velocities; ECG, electrocardiogram; ESRD, end-stage renal disease; LV, left ventricular; PA, pulmonary artery; RA, right atrium; STE, speckle-tracking echocardiography; TDI, tissue Doppler imaging; TTR, transthyretin.



Multisocietal Expert Consensus
RECOMMENDATIONS

Cardiac Magnetic Resonance

Cardiac Magnetic Resonance (CMR) as a Cardiac Imaging Modality for Cardiac Amyloidosis

BASIS OF EVIDENCE

CMR may raise suspicion of disease in 2 scenarios¹:

- 1 Differentiation between cardiac amyloidosis and other cardiomyopathic conditions with increased wall thickening
- 2 Detection of early cardiac involvement in patients presenting with symptoms of systemic amyloidosis

In addition to high-resolution morphologic and functional assessment, CMR is able to provide tissue characterisation.¹

Cardiac amyloidosis is suggested on CMR when the following are observed¹:

- Functional and morphologic assessment:
 - Increased left ventricular (LV) wall thickness, increased LV mass, biatrial enlargement, pericardial effusion, low stroke volume index, increased atrial volume, reduced atrial function, and reduced LV function in advanced cases
- Tissue characterisation:
 - Late gadolinium enhancement (LGE) assessment: Abnormal diffuse or global LGE patterns, including subendocardial LGE, patchy LGE, difficulty in achieving myocardial nulling over a range of inversion times, and dark blood pool signal
 - Abnormal myocardial signal suppression pattern
 - T1 mapping post-contrast: Extracellular volume >0.40

CMR PROS AND CONS^{1,3}

Pros

- CMR may be advantageous in the following scenarios if echocardiographic acoustic windows are poor:
 - To characterise the right ventricle
 - To characterise tissue based on the contrast-enhanced patterns of myocardial infiltration
 - To precisely quantify cardiac chamber volumes and ventricular mass

Cons

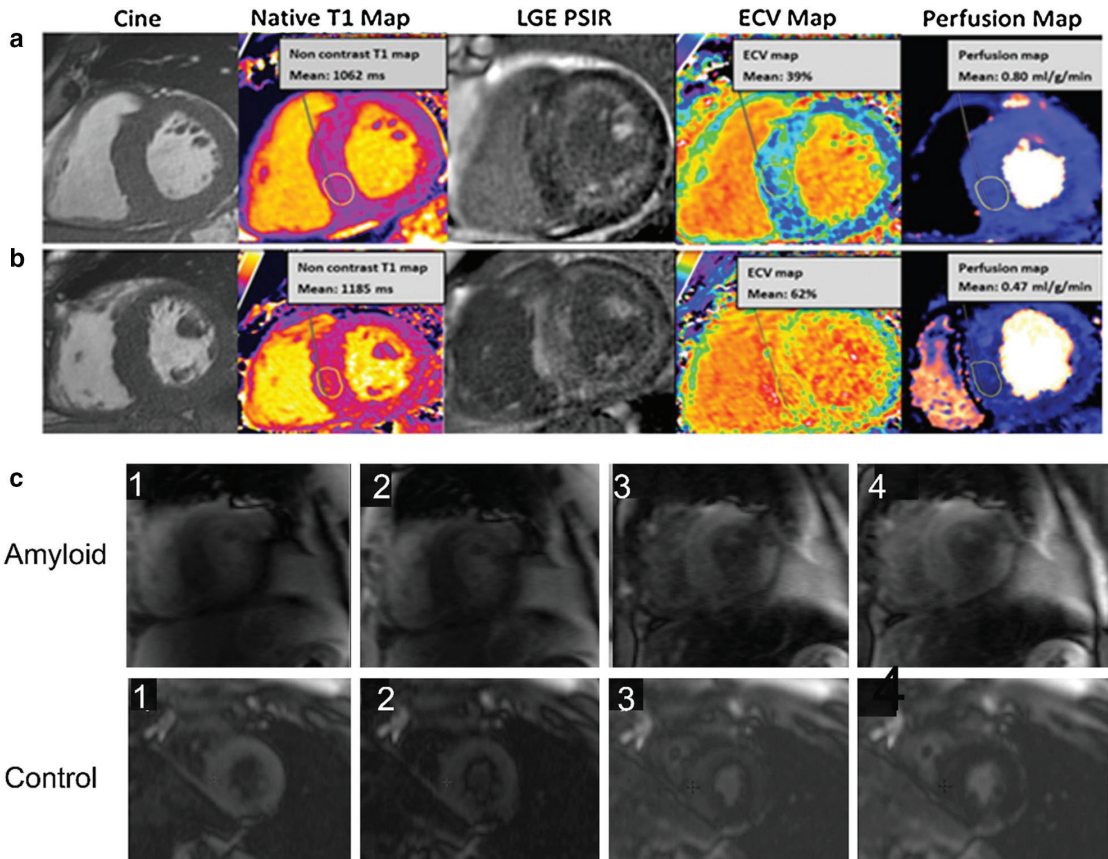
- Cannot distinguish immunoglobulin light chain amyloidosis (AL) from transthyretin amyloid cardiomyopathy (ATTR-CM), requiring evaluation to exclude AL and further imaging studies to definitively diagnose ATTR-CM
- CMR with LGE may be contraindicated in patients with ATTR-CM who have concurrent renal dysfunction
- Restricted to specialty locations and requires specialty equipment and expertise
- Contraindicated with some pacemakers and other implanted hardware
- Long test compared with other imaging modalities
- Some patients may experience claustrophobia

KEY RECOMMENDATIONS FOR THE ROLE OF CMR WHEN CARDIAC AMYLOIDOSIS IS SUSPECTED¹

- Comprehensive CMR-based evaluation of cardiac structure, function, and myocardial tissue characterisation
- In patients with biopsy-proven systemic amyloidosis, typical CMR findings should be combined with structural findings of increased wall thickness and myocardial mass to diagnose cardiac involvement
 - Typical CMR features should prompt further evaluation for cardiac amyloidosis in the absence of documented systemic amyloidosis
- CMR does not definitively distinguish AL from ATTR-CM
- To maximise diagnostic accuracy, CMR parameters should be combined with electrocardiographic, clinical, biomarker, and other imaging findings

CARDIAC AMYLOIDOSIS ON CMR¹

Characteristic Appearance



Two patients [upper and lower row, (a) and (b)] with cardiac amyloidosis: similar mass (cine), but significantly different amyloid burden, with the patient at the bottom (b) showing a significant higher amyloid burden (higher native T1, higher extracellular volume [ECV], transmural LGE) and lower myocardial resting perfusion (also, after adjusting for ECV expansion). (c) Inversion scout images in two patients, upper row amyloid, lower row non-amyloid control. These images show a distinct pattern of myocardial and blood pool nulling. In the non-amyloid subject, the blood pool nulls prior to myocardium; in contrast, in the subject with cardiac amyloidosis, the myocardium nulls prior to the blood pool.

Cardiac Magnetic Resonance (CMR) as a Cardiac Imaging Modality for Cardiac Amyloidosis, continued

RECOMMENDATIONS FOR STANDARDISED INTERPRETATION AND REPORTING OF CMR FOR CARDIAC AMYLOIDOSIS¹

Parameter for acquisition and reporting	Criteria	Notes	Recommendations for reporting
LV function and morphology			
LV function	Biventricular long-axis impairment with relative apical functional sparing	Although LV ejection fraction is typically preserved in cardiac amyloidosis, a reduced LV ejection fraction may be seen in advanced cases	Required
LV wall thickness	Increased LV wall thickness: > laboratory ULN for sex on SSFP cine CMR and increased relative wall thickness >0.42 cm	Increased LV wall thickness is suggestive in the presence of normal or low QRS voltage on ECG and/or concomitant increased right ventricular wall thickness While increased LV wall thickness is typically concentric, it can be asymmetric in ATTR cardiac amyloidosis	Required
Stroke volume index	LV stroke volume index (<35 mL/m ²)	A low stroke volume index is non-specific but suggestive of cardiac amyloidosis	Required
LV mass	LV mass ≥91 g/m ² for men and ≥78 g/m ² for women (with papillary muscle included as part of LV mass measurement)	To quantify myocardial and amyloid mass	Required
Atrial size and function (based on Simpson's method)	Increased left atrial volume >163 mL for men and >131 mL for women Increased right atrial volume >85 mL/m ² Reduced atrial function: <29% for men and <35% for women	Non-specific but important finding to support the diagnosis and potentially provide insight into risk for stroke or arterial embolism	Required
Pericardial effusion	Pericardial effusion	Non-specific, but when coupled with other CMR signs is suggestive of the diagnosis, especially in the setting of normal LV ejection fraction	Required
Amyloid Imaging			
LGE imaging	Abnormal LGE pattern <ul style="list-style-type: none">• Diffuse LGE• Subendocardial LGE• Patchy LGE• Difficulty in achieving myocardial nulling over a range of inversion times• Dark blood pool signal	Standard mag-IR LGE imaging is not recommended given difficulty in selecting the optimal inversion time (TI). Phase-sensitive reconstruction is preferred Data acquisition should be obtained in every other RR interval Quantification of LGE is challenging in amyloidosis and is not recommended for routine clinical practice	Required

Parameter for acquisition and reporting	Criteria	Notes	Recommendations for reporting
Myocardial signal suppression pattern	Abnormal myocardial signal suppression pattern Myocardium nulls before blood pool on Look Locker, Cine IR, or T1 scout sequences		Recommended
Amyloid quantitation			
Native T1 mapping (pre-contrast)	Abnormal T1 mapping (criteria may vary based on the sequence used [MOLLI, ShMOLLI] and the field strength of the magnet)	Assess interstitial amyloid accumulation without gadolinium Reference range should be based on a site's local calibrated values on specific field strengths	Recommended
T1 mapping post-contrast (ECV estimation)	ECV >0.40 is highly suggestive of cardiac amyloidosis	Assess expansion of ECV from interstitial amyloid accumulation A. 1 pre- and 1 post-contrast measurement (15-minute post-contrast injection) B. 1 pre- and 3 post-contrast measurements (5-, 15-, and 25-minutes post-contrast injection)	A. Recommended B. Optional
REPORTING OF CMR FINDINGS IN CARDIAC AMYLOIDOSIS			
An overall interpretation of the CMR findings into categories of: <ul style="list-style-type: none">• Not suggestive: Normal LV wall thickness, normal LV mass, no ventricular LGE, normal atrial size• Strongly suggestive: Increase LV wall thickness, increased LV mass, biatrial enlargement, typical diffuse or global LGE pattern, difficulty achieving myocardial nulling, significantly increased ECV (>0.40), small pericardial and/or pleural effusions• Equivocal: Findings not described above			Required
Interpret the CMR results in the context of prior evaluation			Recommended
Provide follow-up recommendations: Strongly suggestive CMR findings cannot distinguish AL from ATTR cardiac amyloidosis Endomyocardial biopsy is frequently unnecessary in patients with strongly suggestive CMR findings and histologically defined systemic amyloidosis or diagnostic ^{99m} Tc-PYP/DPD imaging Consider evaluation (1) to exclude AL amyloidosis, evaluate for plasma cell dyscrasia (serum and urine immunofixation, serum FLC assay) and (2) to exclude ATTR cardiac amyloidosis, consider imaging with ^{99m} Tc-PYP/DPD			Recommended

T2 mapping is currently not part of the standard clinical amyloidosis imaging protocol
^{99m}Tc-DPD, ^{99m}technetium-labelled 3,3-diphosphono-1,2-propanodicarboxylic acid; ^{99m}Tc-PYP, ^{99m}technetium-labelled pyrophosphate; AL, immunoglobulin light chain amyloid fibril protein; ATTR, transthyretin amyloid fibril protein; EF, ejection fraction; ECV, extracellular volume; FLC, free light chain; IR, inversion recovery; LGE, late gadolinium enhancement; MOLLI, modified Look-Locker inversion recovery; SSFP, steady state free precession; ShMOLLI, shortened modified Look-Locker inversion recovery; ULN, upper limit of normal.

Radionuclide Imaging (^{99m}Tc-PYP/DPD)

^{99m}Tc-DPD, ^{99m}technetium-labelled 3,3-diphosphono-1,2-propanodicarboxylic acid; ^{99m}Tc-PYP, ^{99m}technetium-labelled pyrophosphate.

99mTc-PYP/DPD Radionuclide Imaging as a Diagnostic Modality*

BASIS OF EVIDENCE

Radionuclide imaging with technetium-labelled bone avid radiotracers can definitively and noninvasively diagnose transthyretin amyloid cardiomyopathy (ATTR-CM) once immunoglobulin light chain amyloid fibril protein (AL) is ruled out.^{1†}

- Scintigraphy with ^{99m}Tc-PYP/DPD provides a unique myocardial uptake pattern in amyloid¹
- Studies comparing ^{99m}Tc-PYP/DPD scintigraphy with endomyocardial biopsy (EMB) found that bone radiotracers have avidity for ATTR-CM deposits, whereas avidity for AL cardiac amyloid deposits is minimal or absent¹
- A variety of bone-avid radiotracers like ^{99m}Tc-PYP/DPD compounds can diagnose ATTR-CM¹
 - A multicentre international study of scintigraphy at amyloid centers of excellence demonstrated 100% specificity for ATTR-CM using visual grade 2 or 3 with concurrent testing to rule out AL^{41§}
 - ^{99m}Tc-DPD may also detect extracardiac (skeletal muscle and lung) amyloid infiltration¹
- Both planar and single-photon emission computed tomography (SPECT) imaging should be reviewed and interpreted using visual and quantitative approaches¹
 - SPECT imaging is necessary for studies that show planar myocardial uptake because it can help differentiate myocardial uptake from blood pool or overlying bone uptake¹
- Cardiac scintigraphy with bone-avid radiotracers could reliably differentiate cardiac amyloidosis from other entities that mimic cardiac amyloidosis, such as hypertrophic cardiomyopathy¹

99mTc-PYP/DPD Radionuclide Imaging PROS AND CONS¹

Pros

- Determines amyloid type—critical information that complements cardiac structural and functional analysis
- Offers a definitive diagnosis with high sensitivity and specificity in select patients in whom AL has been ruled out¹
- Whole-body imaging can occur concurrently, which can identify potential multiorgan involvement

Cons

- Not 100% specific for patients with evidence of a plasma cell dyscrasia
- In some mutations, it is possible for patients with hereditary ATTR-CM (hATTR-CM) to have negative radionuclide imaging findings

¹The mechanism for this is unknown.

*A histological diagnosis is needed for patients with evidence of a plasma cell dyscrasia, because the presence of low-grade uptake on a ^{99m}Tc-PYP/DPD scan is not 100% specific for ATTR-CM, and substantial uptake (Grade 2 or 3) has been reported in more than 20% of patients with AL cardiac amyloidosis. Excluding monoclonal process with serum/urine immunofixation and a serum FLC assay in all patients with suspected amyloidosis is recommended.¹

[†]Multicentre study conducted to determine the diagnostic value of bone scintigraphy in ATTR-CM patients. Of 1217 evaluable patients, 374 underwent EMB, and 843 were diagnosed with presence and type or absence of amyloid on basis of extracardiac histology combined with echocardiography with or without cardiac magnetic resonance (CMR).

[§]Rule out AL: testing for presence of monoclonal protein via serum and urine immunofixation + serum free light chain assay.

^{99m}Tc-DPD, ^{99m}technetium-labelled 3,3-diphosphono-1,2-propanodicarboxylic acid; ^{99m}Tc-PYP, ^{99m}technetium-labelled pyrophosphate.

KEY RECOMMENDATIONS FOR THE ROLE OF RADIONUCLIDE IMAGING WHEN CARDIAC AMYLOIDOSIS IS SUSPECTED¹

- Myocardial imaging with ^{99m}Tc-PYP/DPD is highly sensitive and specific to diagnose ATTR-CM and may aid in its early detection
- Myocardial uptake of ^{99m}Tc-PYP/DPD of Grade ≥2 is diagnostic of ATTR-CM and removes the need for EMB when AL is ruled out
- Consider cardiac ^{99m}Tc-PYP/DPD scintigraphy in all patients with unexplained increased LV wall thickness, heart failure with preserved ejection fraction, familial amyloid polyneuropathy (FAP), family history of amyloidosis, degenerative aortic stenosis with low-flow low gradient in the elderly, and a history of bilateral carpal tunnel syndrome

If cardiac amyloidosis is suspected based on clinical, echocardiographic, or CMR findings, then¹:

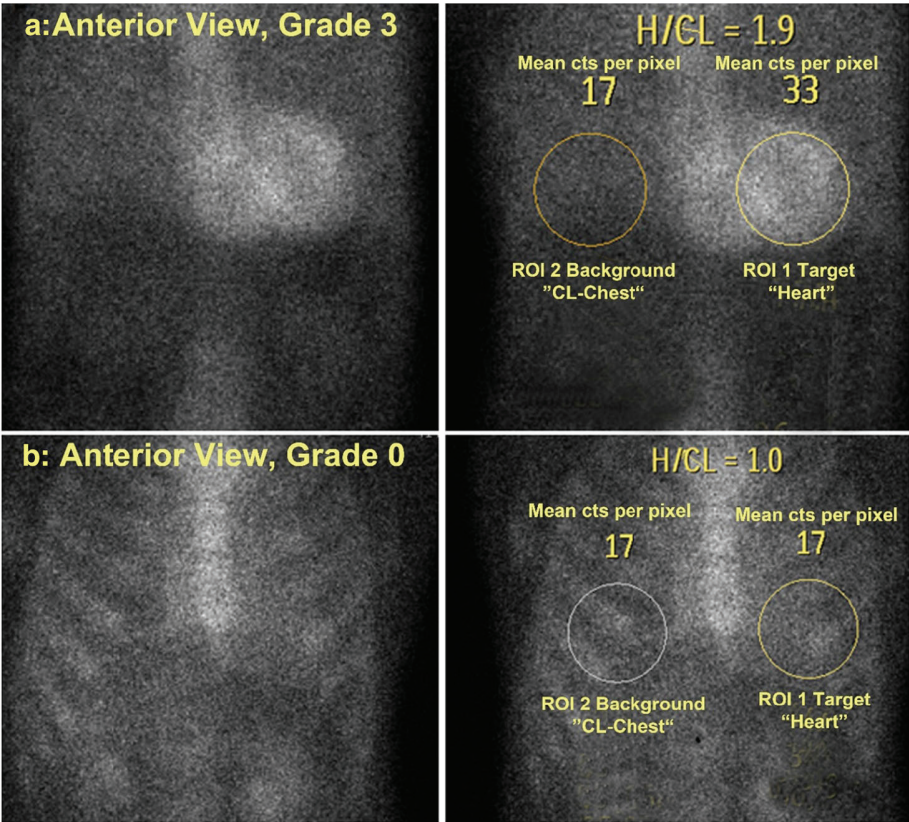
Analyse blood and urine for evidence of a monoclonal protein **and**

Consider ^{99m}Tc-PYP/DPD cardiac scintigraphy if ATTR-CM is suspected and AL has been ruled out

CARDIAC AMYLOIDOSIS ON RADIONUCLIDE IMAGING¹

Characteristic Appearance

Anterior planar chest views one hour after injection of ^{99m}Tc-PYP a patient with Grade 3 (a), and Grade 0 (b) ^{99m}Tc-PYP uptake. On the right are the corresponding H/CL (heart/contralateral lung) lung-ratio methodology with measurement of mean counts per pixel for target (heart) and background (contralateral chest). As shown in this figure, the ROI's (region of interest) should be positioned to minimise overlap with sternal or focal rib uptake and maximise coverage of the heart without including adjacent lung.



99mTc-PYP/DPD Radionuclide Imaging as a Diagnostic Modality, continued

RECOMMENDATIONS FOR INTERPRETATION OF 99mTc-PYP/DPD FOR CARDIAC AMYLOIDOSIS

Step 1: Visual interpretation to diagnose ATTR cardiac amyloidosis	
<ul style="list-style-type: none">Evaluate planar and SPECT images to confirm diffuse radiotracer uptake in the myocardium	
<ul style="list-style-type: none">Differentiate myocardial radiotracer uptake from residual blood pool activity, focal myocardial infarct, and overlapping bone (e.g., from rib hot spots from fractures). If excess blood-pool activity is noted on the 1-hour SPECT images, recommend repeat SPECT imaging at 3 hours	
<ul style="list-style-type: none">If myocardial tracer uptake is visually present on SPECT, proceed to step 2, semi-quantitative grading to distinguish ATTR from AL cardiac amyloidosis using either the 1- or 3-hour approach	
Step 2: Semi-quantitative grading to distinguish AL from ATTR cardiac amyloidosis (1- or 3-hour approach)	
1-Hour Approach (validated for 99mTc-PYP): <ul style="list-style-type: none">An elliptical/circular ROI should be drawn over the heart on the anterior planar images with care to avoid sternal overlap and with size adjusted to maximise coverage of the heart without inclusion of adjacent lung. This ROI (same size) should be mirrored over the contralateral chest to adjust for background and rib uptake (See CARDIAC AMYLOIDOSIS ON RADIONUCLIDE IMAGING on page 19)A H/CL ratio is calculated as the fraction of heart ROI mean counts to contralateral chest ROI mean countsH/CL ratios of ≥1.5 at one hour can accurately identify ATTR cardiac amyloidosis if systemic AL amyloidosis is excluded	
3-Hour Approach: <ul style="list-style-type: none">Examine 3-hour images for relative tracer uptake in the myocardium relative to ribs and grade using the following scale:	
Grade 0	No myocardial uptake and normal bone uptake
Grade 1	Myocardial uptake less than rib uptake
Grade 2	Myocardial uptake equal to rib uptake
Grade 3	Myocardial uptake greater than rib uptake with mild/absent rib uptake

Grade 2 or Grade 3 uptake is consistent with ATTR cardiac amyloidosis if a monoclonal plasma cell dyscrasia is excluded, as this degree of uptake can be seen in >20% of patients with AL cardiac amyloidosis. Grade 0 and Grade 1 uptake may be observed in AL cardiac amyloidosis and warrants further evaluation to exclude AL amyloidosis. The writing group would like to emphasise the importance of excluding a monoclonal process with serum/urine immunofixation and a serum free light-chains assay in all patients with suspected amyloidosis.

RECOMMENDATIONS FOR STANDARDISED REPORTING OF 99mTc-PYP/DPD IMAGING FOR CARDIAC AMYLOIDOSIS¹

Parameters	Elements
Demographics	Patient name, age, sex, reason for the test, date of study, prior imaging procedures, biopsy results if available (Required)
Methods	Imaging technique, radiotracer dose and mode of administration, interval between injection and scan, scan technique (planar and SPECT) (Required)
Findings	Image quality Visual scan interpretation (Required) Semi-quantitative interpretation in relation to rib uptake (Required) Quantitative findings H/CL lung ratio (Optional; recommended for positive scans)
Ancillary findings	Whole-body imaging if planar whole-body images are acquired (Optional) Interpret CT for attenuation correction if SPECT/CT scanners are used (Recommended)
Conclusions	1. An overall interpretation of the findings into categories of 1) not suggestive of ATTR cardiac amyloidosis; 2) equivocal for ATTR cardiac amyloidosis or 3) strongly suggestive of ATTR cardiac amyloidosis <ol style="list-style-type: none">Not suggestive: A semi-quantitative visual grade of 0Equivocal: If myocardial uptake of 99mTc-PYP/DPD is visually confirmed, a semi-quantitative visual grade of 1 or H/CL ratio 1-1.5Strongly suggestive: If myocardial uptake of 99mTc-PYP/DPD is visually confirmed, a semi-quantitative visual grade of 2 or 3 2. Interpret the results in the context of prior cardiac evaluation and evaluation for systemic AL amyloidosis using serum-free light chain assay, serum immunofixation, and urine immunofixation studies. A 99mTc-PYP/DPD scan does not exclude AL cardiac amyloidosis. Therefore: <ol style="list-style-type: none">If echo/CMR are strongly suggestive of cardiac amyloidosis, and 99mTc-PYP/DPD is negative or equivocal, consider further evaluation for AL amyloidosis by serum FLCs, serum, and urine immunofixation and referral to a haematologist or an amyloidosis expert. EMB may be consideredA positive 99mTc-PYP/DPD scan with abnormal FLC evaluation, consider referral to a haematologist or an amyloidosis expert

99mTc-DPD, 99mtechnetium-labelled 3,3-diphosphono-1,2-propanodicarboxylic acid; 99mTc-PYP, 99mtechnetium-labelled pyrophosphate; AL, immunoglobulin light chain amyloid fibril protein; ATTR, transthyretin amyloid fibril protein; CT, computed tomography; EMB, endomyocardial biopsy; FLC, free light chain; H/CL, heart to contralateral lung; ROI, region of interest; SPECT, single-photon emission computed tomography.

OTHER RADIONUCLIDE IMAGING MODALITIES

Other radionuclide imaging modalities may also play a role in the noninvasive diagnosis of cardiac amyloidosis, including:

- Targeted amyloid binding 18F-positron emission tomography (PET) tracers, which seem to bind to both ATTR and AL and are highly specific to image amyloid deposits
- Investigational PET tracers include C-Pittsburgh compound B (11C-PIB) and the fluorine-labelled compounds: 18F-florbetapir, 18F-florbetaben, and 18F-flutemetamol
- Another established tracer for imaging myocardial denervation, 123I-meta-iodobenzylguanidine (mIBG), which has been used to image myocardial denervation in familial ATTR cardiac amyloidosis

Endomyocardial Biopsy (EMB) to Diagnose Cardiac Amyloidosis

EMB is a known diagnostic tool for cardiac amyloidosis. Congo red staining with apple-green birefringence under polarised light is indicative of cardiac amyloidosis.^{1,2} Still, EMB comes with limitations and risks, necessitating a multimodality approach using noninvasive imaging techniques, such as echocardiography, cardiac magnetic resonance, and radionuclide imaging, all of which have evolved as the principal means for cardiac amyloidosis diagnosis and disease management.¹

EMB PROS AND CONS ^{1,2}	
Pros	Cons
<ul style="list-style-type: none">• Considered the gold standard for the diagnosis of cardiac amyloidosis• 100% accuracy in the detection of amyloid deposits	<ul style="list-style-type: none">• Invasive• Risk for complications• Requires specialised location and pathologic expertise• Unable to identify whole-heart amyloid burden, evaluate systemic disease burden, or assess response to therapy



Multisocietal Expert Consensus RECOMMENDATIONS

No existing noninvasive diagnostic tools can individually diagnose cardiac amyloidosis AND identify aetiologic subtype, necessitating a multimodality cardiac imaging approach to identify this underdiagnosed group of diseases, which may pave the way for future noninvasive diagnostic guidelines for cardiac amyloidosis.¹

Expert Consensus Recommendations for Diagnosis of Cardiac Amyloidosis²

Criteria for Diagnosis	Subtype
Histological Diagnosis of Cardiac Amyloidosis: Endomyocardial Biopsy*	
1. Endomyocardial biopsy positive for cardiac amyloidosis with Congo red staining with apple-green birefringence under polarised light; typing by immunohistochemistry and/or mass spectrometry at specialised centres	AL, ATTR, Other subtypes
Histological Diagnosis of Cardiac Amyloidosis: Extracardiac Biopsy	
1. ATTR cardiac amyloidosis is diagnosed when below criteria are met: a. Extracardiac biopsy proven ATTR amyloidosis AND b. Typical cardiac imaging features (as defined below)	ATTR
2. AL cardiac amyloidosis is diagnosed when below criteria are met: a. Extracardiac biopsy proven AL amyloidosis AND b. Typical cardiac imaging features (as defined below) OR c. Abnormal cardiac biomarkers: abnormal age-adjusted NT-pro BNP or abnormal Troponin T/I/Hs-Troponin with all other causes for these changes excluded	AL
Clinical Diagnosis of ATTR Cardiac Amyloidosis: ^{99m}Tc-PYP/DPD	
3. ATTR cardiac amyloidosis is diagnosed when below criteria are met: a. ^{99m} Tc-PYP/DPD Grade 2 or 3 myocardial uptake of radiotracer AND b. Absence of a clonal plasma cell process as assessed by serum FLCs and serum and urine immunofixation AND c. Typical cardiac imaging features (as defined below)	ATTR
Typical Imaging Features of Cardiac Amyloidosis	
Typical cardiac echo or CMR or PET features: ANY of the below imaging features <u>with all other causes for these cardiac manifestations, including hypertension, reasonably excluded</u>	
1. Echo a. LV wall thickness >12 mm b. Relative apical sparing of global LS ratio (average of apical LS/average of combined mid+basal LS >1) c. ≥ Grade 2 diastolic dysfunction†	ATTR/AL
2. CMR a. LV wall thickness >ULN for sex on SSFP cine CMR b. Global ECV >0.40 c. Diffuse LGE‡ d. Abnormal gadolinium kinetics typical for amyloidosis, myocardial nulling prior to blood pool nulling	ATTR/AL
3. PET: ¹⁸ F-florbetapir† or ¹⁸ F-florbetaben PET†‡ a. Target to background (LV myocardium to blood pool) ratio >1.5 b. Retention index >0.030 min ⁻¹	ATTR/AL

These consensus recommendations were based on moderate-quality evidence from one or more well-designed, well-executed nonrandomised studies, observational studies, registries, or meta-analyses of such studies. The PET recommendations were based on more limited data

*Endomyocardial biopsy should be considered in cases of equivocal ^{99m}Tc-PYP/DPD scan. When ^{99m}Tc-PYP/DPD is positive in the context of any abnormal evaluation for serum/urine immunofixation or serum free light chain assay, or MGUS, this should not be seen as diagnostic for ATTR cardiac amyloidosis. In these instances, referral to a specialist amyloid centre for further evaluation and consideration of biopsy is recommended

†Off-label use of FDA-approved commercial products

‡¹⁸F-flutemetamol not studied systematically in the heart. ¹¹C-Pittsburgh B compound is not FDA approved and not available to sites without a cyclotron in proximity

^{99m}Tc-DPD, ^{99m}technetium-labelled 3,3-diphosphono-1,2-propanodicarboxylic acid; ^{99m}Tc-PYP, ^{99m}technetium-labelled pyrophosphate; AL, immunoglobulin light chain amyloid fibril protein; ATTR, transthyretin amyloid fibril protein; CMR, cardiac magnetic resonance; ECV, extracellular volume; FLC, free light chain; LGE, late gadolinium enhancement; LS, longitudinal strain; LV, left ventricular; MGUS, monoclonal gammopathy of uncertain significance; NT-pro BNP, N-terminal-pro brain natriuretic peptide; PET, positron emission tomography; SSFP, steady state free precession.

References: 1. Dorbala S, Ando Y, Bokhari S, et al. ASNC/AHA/ASE/EANM/HFSA/ISA/SCMR/SNMMI expert consensus recommendations for multimodality imaging in cardiac amyloidosis: part 1 of 2—evidence base and standardized methods of imaging [published online ahead of print August 29, 2019]. *J Nucl Cardiol*. doi: 10.1007/s12350-019-01760-6. 2. Dorbala S, Ando Y, Bokhari S, et al. ASNC/AHA/ASE/EANM/HFSA/ISA/SCMR/SNMMI expert consensus recommendations for multimodality imaging in cardiac amyloidosis: part 2 of 2—diagnostic criteria and appropriate utilization [published online ahead of print August 29, 2019]. *J Nucl Cardiol*. doi: 10.1007/s12350-019-01761-5. 3. Laboratory of Cardiac Energetics. National Heart, Lung, and Blood Institute Division of Intramural Research website. What are the technological advantages and limitations (disadvantages) of MRI? <https://dir.nhlbi.nih.gov/labs/lce/cmri/mri-advantages-limitation.asp>. Accessed November 14, 2019. 4. Gillmore JD, Maurer MS, Falk RH, et al. Nonbiopsy diagnosis of cardiac transthyretin amyloidosis. *Circulation*. 2016;133(24):2404-2412.

The health information contained in this piece is provided for educational purposes only.
Content adapted and tables and images reproduced with permission from ASNC. ©2019 American Society of Nuclear Cardiology.
© 2020 Pfizer Inc. All rights reserved. April 2020 PP-RDP-IRL-0070